INTERNATIONAL
ENDODONTIC JOURNAL

doi:10.1111/iej.12946

REVIEW

External cervical resorption: part 2 – management

S. Patel[1,2], F. Foschi[1], R. Condon[1], T. Pimentel[1] & B. Bhuva[1]

[1]Department of Endodontology, King's College London Dental Institute, London; and [2]Specialist Practice, London, UK

Abstract

Patel S, Foschi F, Condon R, Pimentel T, Bhuva B. External cervical resorption: part 2 – management. *International Endodontic Journal*, **51**, 1224–1238, 2018.

Effective management of external cervical resorption (ECR) depends on accurate assessment of the true nature and accessibility of ECR; this has been discussed in part 1 of this 2 part article. This aim of this article was firstly, to review the literature in relation to the management of ECR and secondly, based on the available evidence, describe different strategies for the management of ECR. In cases where ECR is supracrestal, superficial and with limited circumferential spread, a surgical repair without root canal treatment is the preferred approach. With more extensive ECR lesions, vital pulp therapy or root canal treatment may also be indicated. Internal repair is indicated where there is limited resorptive damage to the external aspect of the tooth and/or where an external (surgical) approach is not possible due to the inaccessible nature of subcrestal ECR. In these cases, root canal treatment will also need to be carried out. Intentional reimplantation is indicated in cases where a surgical or internal approach is not practical. An atraumatic extraction technique and short extraoral period followed by 2-week splinting are important prognostic factors. Periodic reviews may be indicated in cases where active management is not pragmatic. Finally, extraction of the affected tooth may be the only option in untreatable cases where there are aesthetic, functional and/or symptomatic issues.

Keywords: external cervical resorption, intentional replantation, management.

Received 9 March 2018; accepted 30 April 2018

Introduction

The aim of treatment for teeth diagnosed with ECR, which are considered to be restorable, is to retain them in a healthy and functional state and improve aesthetics when indicated.

The objectives of treatment for ECR are excavation of the resorptive tissue, sealing of the hard tissue defect with an aesthetic biocompatible material and prevention of recurrence of ECR (Patel *et al.* 2016b).

Treatment options for ECR include the following:

- external repair of the resorptive defect ± endodontic treatment,
- internal repair and root canal treatment,
- intentional replantation,
- periodic review (untreatable teeth),
- extraction (untreatable teeth).

The treatment of ECR depends on the severity and location of the resorptive defect, as well as the restorability of the tooth. Successful management of ECR requires accurate evaluation of the true extent (nature) of the lesion. However, periapical radiographs (PR) have several limitations which commonly result in underestimation of the extent of ECR (Vaz de Souza *et al.* 2017). As already described in part 1 of this review, the use of CBCT provides not only more accurate determination of the true nature of ECR, but also more appropriate treatment planning (Ee *et al.* 2014, Patel *et al.* 2016b, Rodríguez *et al.* 2017a,b).

As described in part 1 of this 2 part series, an electronic literature search was carried out and included the databases MEDLINE (Ovid), PubMed and EMBASE.

Correspondence: Dr. Shanon Patel, Department of Endodontology, Kings College Dental Institute, Floor 25 – Tower Wing, Guys Hospital, London SE1 9RT, UK (e-mail: shanonpatel@gmail.com).

The cut-off date was set to October 2017. In addition, complementary searches were also carried out in November and December 2017. With the available evidence, a systematic review of randomized controlled trials for the management of ECR was not possible due to the lack of available data. Treatment is generally described in review papers, book chapters and case (series) reports. There is no general consensus in the scientific literature with respect to treatment protocols for ECR. This aim of this article was first to review the literature in relation to the management of ECR and second based on the available evidence describe a consensus approach on the management of ECR.

Treatment

The management of ECR is dependent on the accessibility and the restorability of the lesion. When a preoperative CBCT scan is taken, the treatment options can be confidently discussed with the patient and 'exploratory' treatment may be avoided (Rodríguez *et al.* 2017a,b). The CBCT scan will confirm the true nature of the resorptive lesion and provide a visual aid for the clinician to convey important information to the patient (e.g. prognosis, treatment options).

Mavridou *et al.* (2016) described the common characteristics of ECR in teeth with vital pulps. They invariably found the presence of one or more portals of entry with three-dimensional spread of the resorption defect. Supraosseous portals of entry will usually result in crater-like lesions containing predominantly fibrovascular tissue. These are usually managed by an external approach. Endodontic treatment may also be required if ECR has perforated the root canal system or is likely to do so during the course of ECR repair.

Small, usually inaccessible entry points may expand circumferentially and apicocoronally around the root canal space. These are best managed with an internal approach, that is endodontic treatment and orthograde restoration of the ECR defect.

External repair with or without endodontic treatment

Smaller lesions have the most favourable outcome where typically the pulp is not involved. These lesions would be considered as Heithersay class 1 and class 2 (Heithersay 1999), or classes 1Ad, 2Ad, 2Bd using the 3D Patel classification system (Patel *et al.* 2018).

Depending on the extent of the lesion, either an intracrevicular incision or mucoperiosteal flap will need to be reflected to allow adequate access to the ECR for curettage of the resorptive lesion's granulomatous tissue from both the root and periodontium (Frank & Torabinejad 1998) (Fig. 1).

It is essential that treatment is carried out with the aid of a dental operating microscope or loupes. Granulomatous tissue should be removed with sharp excavators. Persistent bleeding is indicative of communicating channels from the periodontium extending into the cavity and/or fibro-osseous tissue that may be difficult to differentiate from dentine and reparative hard tissue. Incomplete removal of the resorptive tissue is likely to result in the recurrence of ECR (Patel *et al.* 2009). Resorptive defects containing significant amounts of reparative tissue, especially when contiguous with the adjacent dentine require discriminate removal of the reparative tissue with ultrasonic instruments. It may be challenging to differentiate between sound dentine and fibro-osseous deposits, hence the importance of magnification and illumination.

An accessible channel of ECR may be difficult to identify and/or access, 90% aqueous trichloroacetic acid (TCA) may be applied to the resorptive cavity to promote coagulation necrosis of this tissue as it penetrates the smaller, more inaccessible recesses and resorptive channels which may not be identified and debrided by mechanical instrumentation alone (Heithersay 1999, Schwartz *et al.* 2010).

Care must be taken when using TCA due to the potential irritation it may inadvertently cause following contact with the oral mucosa and/or skin. A small cotton pledget or microbrush should be dipped into TCA and then gently pressed to remove excess liquid before carefully applying it to the resorptive site until coagulation necrosis occurs (usually within 3–4 min). The areas immediately adjacent to the ECR defect may be protected with application of glycerol and single tooth isolation or split dam technique to prevent inadvertent contact of TCA onto the adjacent tissues (Heithersay & Wilson 1988, Heithersay 1999). Alternatively, 3–5% sodium hypochlorite may be used in a similar way to TCA. Undermined dentine and enamel should be removed with a bur in a surgical high-speed handpiece.

In cases where there is communication with the oral environment, the excavated cavity should be restored with a composite resin (Fig. 1) or glass–ionomer cement restoration (Trope 2002, Heithersay 2007).

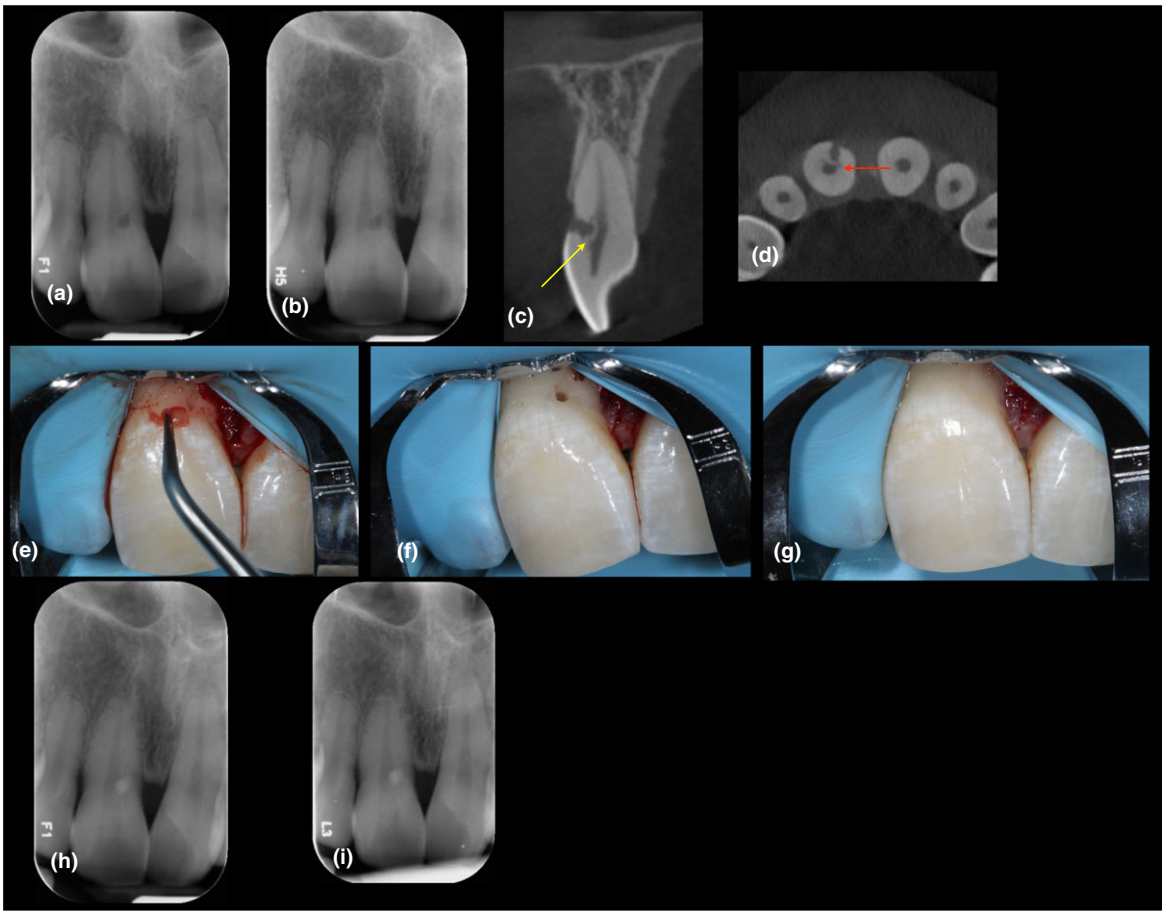

Figure 1 External repair (a, b) parallax radiographs of the maxillary left central incisor reveal a radiolucency in the coronal third of the root canal (c) a reconstructed sagittal (d) and axial CBCT slices confirm the presence and true extent of the ECR lesion, note how the ECR has not penetrated the root canal (yellow arrow); this information is important for treatment planning purposes, (e–g) the operator knows the exact dimensions (yellow and red arrows) of the lesion and therefore only needs to raise a small mucoperiosteal flap, to excavate and seal the resorptive defect. (h) Immediate post-fill and (i) 1-year review. Courtesy of Daniel Vaz, KCL, UK, in CBCT in Endodontics, Patel, Harvey, Shemesh, Durack, Quintessence.

An indirect or direct pulp cap using a bioactive endodontic cement such as Biodentine, (Biodentine™ Septodont, Saint-Maur-des-fosses, France) or MTA (ProRoot MTA, Dentsply Sirona Endodontics, Tulsa, OK, USA; MTA-Angelus, Angelus, Londrina-PR, Brazil) may be indicated if the pulp is close to being or is perforated, for example, Patel class 1Ap, 2Ap, 2Bp (Nair *et al.* 2008, Nowicka *et al.* 2013, Parirokh *et al.* 2018). These materials have excellent sealing ability (Torabinejad & Parirokh 2010, Koubi *et al.* 2012, Raskin *et al.* 2012, Ramezanali *et al.* 2017), antibacterial properties (Parirokh & Torabinejad 2010) and biocompatibility (Sultana *et al.* 2018, Tomas-Catala *et al.* 2018). They also promote reparative dentine formation, cementum formation and osteoblast differentiation (Koh *et al.* 1997, Zanini *et al.* 2012, Torabinejad *et al.* 2018). The remaining cavity may then be restored with a direct plastic adhesive restoration at the same visit.

Bioactive restorative materials such as Biodentine (Septodont, Lancaster, PA, USA) may also be used for the complete restoration of subgingival ECR cavities which communicate with the oral cavity (Koubi *et al.* 2012, Rajasekharan *et al.* 2014). These bioactive materials have a reasonable aesthetic appearance, but have also been shown to result in PDL attachment (Yan *et al.* 2010). In cases where aesthetic demands are high, for example the labial aspect of maxillary

incisor teeth, then 3–4 mm of the superficial Biodentine may be removed at the same visit and the remaining cavity restored with a glass ionomer and/or composite resin restoration (Karypidou *et al.* 2016, Patel & Vincer 2017).

Endodontic treatment may be required if ECR has perforated the root canal system and/or there are symptoms and/or signs of irreversible pulpitis, pulp necrosis and/or apical periodontitis (Fig. 2). In these situations, the root canal should be identified, accessed and occluded by inserting an appropriately sized gutta-percha point to maintain the patency of the canal(s) during the subsequent excavation and restoration of the ECR defect (as described above). Once the ECR defect has been restored, the mucoperiosteal flap may be repositioned and sutured after which endodontic treatment may be completed. This approach first prevents the unintentional blockage of the root canal and second provides a barrier against which the ECR restorative material may be condensed against. The endodontic treatment may be completed using conventional protocols (Patel *et al.* 2016a).

Heithersay (2007) reviewed the outcome of 101 surgically treated ECR cases and reported a 100%, 77.8% and a 12.5% success rate for class 1 and 2 (combined), 3 and 4 lesions, respectively. The results indicate that more extensive and potentially more inaccessible lesions had a poorer prognosis. As cases treated in this study were all assessed with radiographs, it is likely that the size and nature of ECR may have been underestimated and not fully appreciated, respectively. This may have contributed to the poorer outcome results with class 3 and 4 lesions.

Internal repair

This treatment option is indicated when ECR is close to or has perforated the pulp chamber, an external (surgical) approach might not be possible due to lack of accessibility and/or result in excessive removal of sound tooth structure removal to access the ECR defect. This will be particularly relevant to Patel class 2Cp, 2Dp, 3Cp and 3Dp (Patel *et al.* 2018). An internal approach is preferred in these cases, particularly when the entry point(s) is small, intraosseous and apical to the epithelial junction (as determined by CBCT). The management involves endodontic treatment and subsequent restoration of the resorptive defect.

Endodontic treatment may be completed in a single visit when there is no, or only a small communication between the root canal space and the resorptive lesion. After completion of the endodontic treatment, the access cavity should be extended to encompass the ECR lesion (Fig. 3). Long-shanked friction grip or latch grip burs in the fast or slow handpieces,

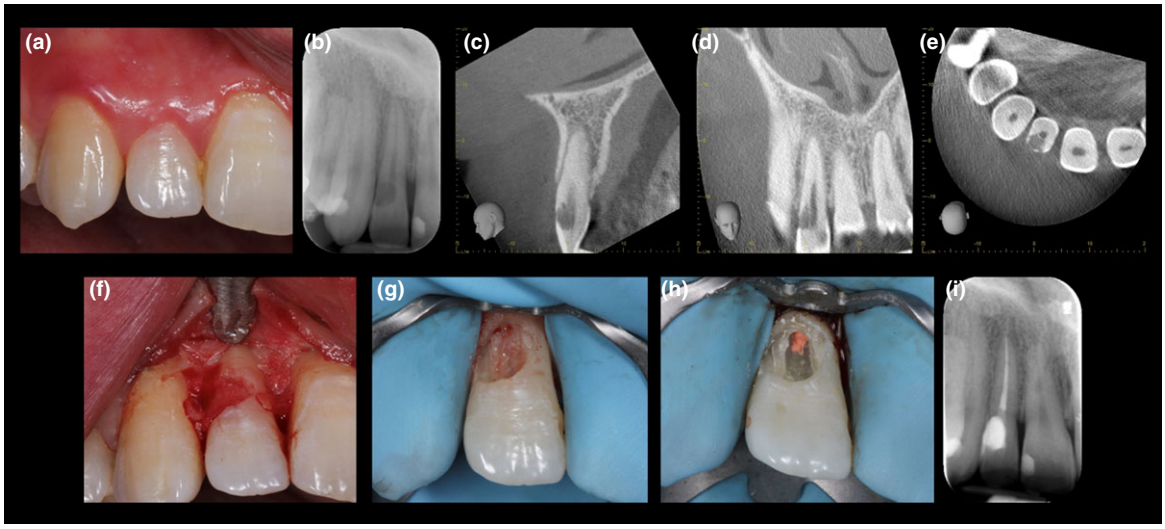

Figure 2 External repair with root canal treatment (a) preoperative image of 12 with symptoms of irreversible pulpitis and pink discoloration, radiograph confirms ECR, (b–d) sagittal, coronal and axial reconstructed CBCT images confirm 2,B,p ECR lesion. (e) Mucoperiosteal flap reflected, (f) after rubber dam isolation and (g) excavation of ECR lesion, (h) root canal treatment via labial access, and (i) post-root canal radiograph after restoration of access cavity with composite resin.

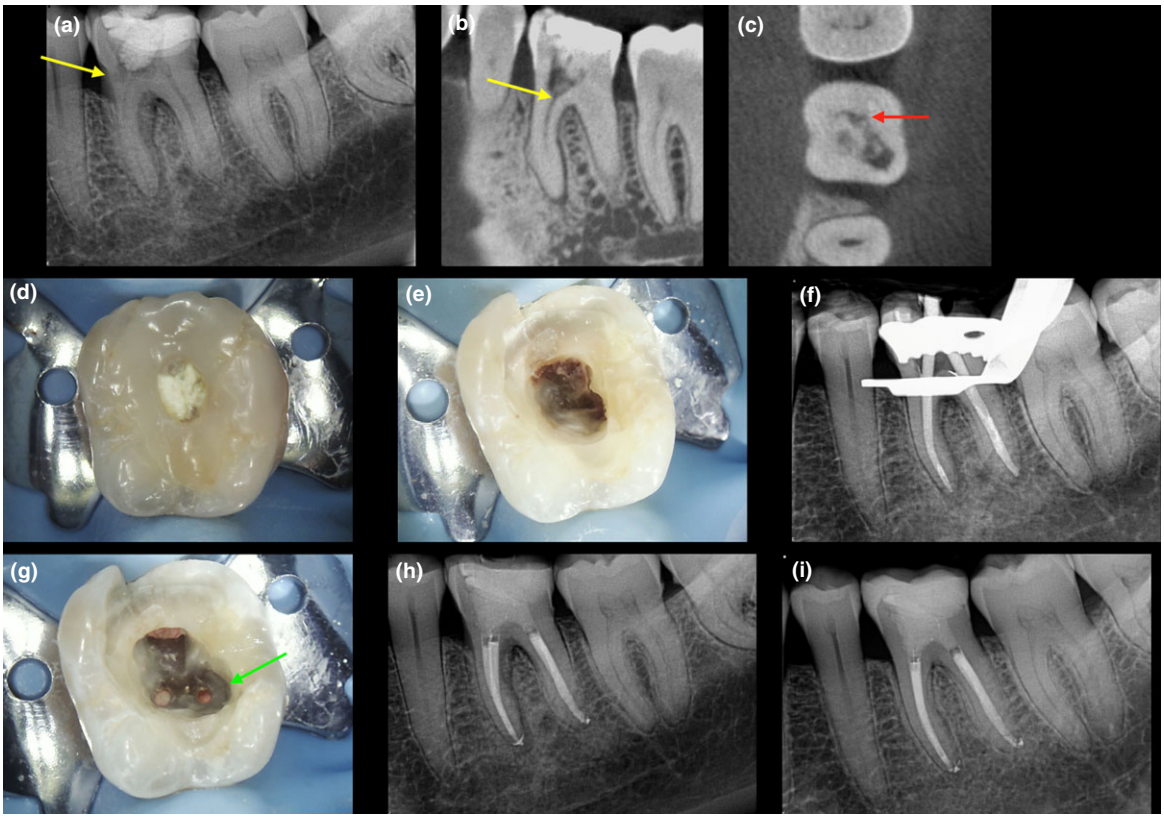

Figure 3 Internal repair with root canal treatment. (a) Preoperative radiograph of a tooth with symptoms of chronic apical periodontitis with signs of ECR (yellow arrow), (b) sagittal and (c) axial CBCT slices confirm the extensive nature of ECR which extends distally (red arrow), (d) prior to access cavity preparation, (e) initial access cavity preparation reveals the partially reparative nature of ECR, (f) master point radiograph, (g) root canal treatment completed; note the extent of the cavity after complete removal of the ECR lesion (green arrow), (h) post-treatment radiograph, the access cavity was restored with Biodentine and a direct plastic restoration (i) 3-year follow-up radiograph.

respectively, and/or endodontic ultrasonic tips should be used in conjunction with magnification (Frank 1981).

With larger ECR lesions, communication with the root canal space before or during endodontic treatment is likely to occur. In these cases, an endodontic access cavity should be prepared to allow both the root canals and the resorptive lesion to be accessed. As previously described, long shank burs and ultrasonic endodontic tips should be used. Any (potential) perforations between the ECR lesion(s) and the adjacent PDL should be temporarily compacted with polytetrafluoroethylene (PTFE) tape. Sodium hypochlorite may then be used to dissolve the granulomatous tissue and arrest bleeding within the resorptive lesion, as well as disinfecting the root canal system. Endodontic treatment may then be completed.

A calcium hydroxide paste may be applied as an interappointment medicament to the resorptive defect if the fibrovascular ECR tissue bleeds persistently. The calcium hydroxide will promote coagulation necrosis (Aeinehchi *et al.* 2003). In addition, the alkaline pH will downregulate osteoclastic function and upregulate osteoblastic activity (Narita *et al.* 2010).

After completion of endodontic treatment, the ECR and endodontic access cavity may be restored with a direct plastic restoration such as composite resin or glass–ionomer cement. Alternatively, a bioactive material such as Biodentine may be used as a dentine substitute (Fig. 3), over which a thin layer of glass–ionomer cement and/or composite resin may be placed (Salzano & Tirone 2015, Patel & Vincer 2017). The use of a bioactive material will result in a high pH which may impair the osteoclastic action of

any residual ECR remnants (Arnett 2008, Gandolfi *et al.* 2017), thus arresting the resorptive process.

Intentional reimplantation

Intentional reimplantation is the intentional 'extraction and reinsertion of an endodontically treated tooth into its socket' (Bender & Rossman 1993). It is indicated in specific situations when (non)-surgical endodontic (re-) treatment is unfeasible and/or contraindicated (Cho *et al.* 2016). The aim of intentional reimplantation is to retain the tooth in a functional state, ideally with complete healing of the periradicular tissues (Grossman 1982, Cho *et al.* 2016).

Intentional reimplantation has been extensively described as a viable alternative for the management of endodontic disease which is not accessible via non-surgical or surgical endodontic treatment, such as where the roots are in close proximity to anatomical structures such as the inferior alveolar nerve or the mental nerve, there is a thick buccal cortical plate (Patel *et al.* 2016c) or where there are extensive palato-gingival grooves (Garrido *et al.* 2016).

The aims and rationale of treatment are the same regardless of whether managing endodontic problems associated with the periapical (e.g. periapical periodontitis) or periradicular (e.g. external cervical resorption) tissues. Indications for use in resorptive cases include cases where ECR is inaccessible to surgery, for example, interproximally or middle/apical-third of roots.

The rationale for intentional reimplantation is largely based on previous research into the treatment of avulsed teeth and their subsequent successful reimplantation, with the aim of preventing external replacement resorption (ERR) from occurring (Weine 1980, Andersson *et al.* 2012).

Contraindications to intentional reimplantation include teeth with advanced periodontal disease (Bender & Rossman 1993), and where crown and/or root fracture is likely during the course of the extraction, for example, with long and curved roots (Bender & Rossman 1993).

Previously, intentional reimplantation was considered by many to be a treatment of last resort (Greiner & Hawkins 1991) and viewed as 'one of the most unreliable procedures in the dental field' (Weine 1980). The high survival rate of dental implants is one of the reasons for intentional reimplantation being overlooked as a viable treatment option for maintaining a tooth (Mainkar 2017). However, more recent evidence, where stringent treatment protocols based on improved understanding of root resorption and splint protocols, has confirmed that intentional reimplantation is more predictable than previously thought, and as such, is a viable treatment option in certain cases (Torabinejad *et al.* 2015, Cho *et al.* 2016, Becker 2018).

It is now widely accepted that atraumatic extraction (Choi *et al.* 2014) and minimizing extraoral dry time (EDT) to less than 15 min (Torabinejad *et al.* 2015, Cho *et al.* 2016) are key prognostic factors for the success of IR. Preservation of viable cementum and periodontal fibres is paramount to reduce the likelihood of external replacement resorption and therefore the success of intentional reimplantation (Becker 2018). The shorter the EDT, the more likely the chance of maintaining PDL fibre and cementum viability, thus limiting the subsequent inflammatory response (Andreasen & Hjorting-Hansen 1966, Andreasen 1981, Trope 2011). Replanting the tooth within 15 min of its extraction is essential to achieve optimal PDL healing (Tsukiboshi 2002, Cho *et al.* 2016, Jang *et al.* 2016).

The use of periotomes (Asgary *et al.* 2014, Sharma *et al.* 2015) or microsurgical blades (Jang *et al.* 2016) will reduce injury to the PDL and cementum (Fig. 4). If it is necessary to use forceps, they should only engage the crown of the tooth, therefore minimizing damage to the periodontal tissues (Kingsbury & Wiesenbaugh 1971, Nosonowitz 1972, Kratchman 1997, Niemczyk 2001). Orthodontic extrusion for 2–3 weeks will also facilitate extraction (Choi *et al.* 2014).

The use bioactive materials such as MTA (Choi *et al.* 2014, Cho *et al.* 2016) as opposed to amalgam which was commonly used in earlier studies has also been shown to improve the outcome of intentional reimplantation (Frank *et al.* 1992).

More recent intentional reimplantation outcome studies using modern intentional reimplantation treatment protocols, that is extraoral time of less than 15 min and restoration with a bioactive material, have reported higher survival rates (Cho *et al.* 2016). In this study of 159 teeth, a retention rate of 93% was observed after 12 years (Cho *et al.* 2016). A further outcome study of 287 teeth demonstrated an overall success rate of 89.5% and a survival rate of 95%; the mean follow-up period was 25 months (Choi *et al.* 2014). The survival rate was increased to 98% when a short course of orthodontic extrusion was carried out prior to IR. This course of orthodontic extrusion facilitated atraumatic extraction by increasing tooth mobility and encouraging an increased PDL volume.

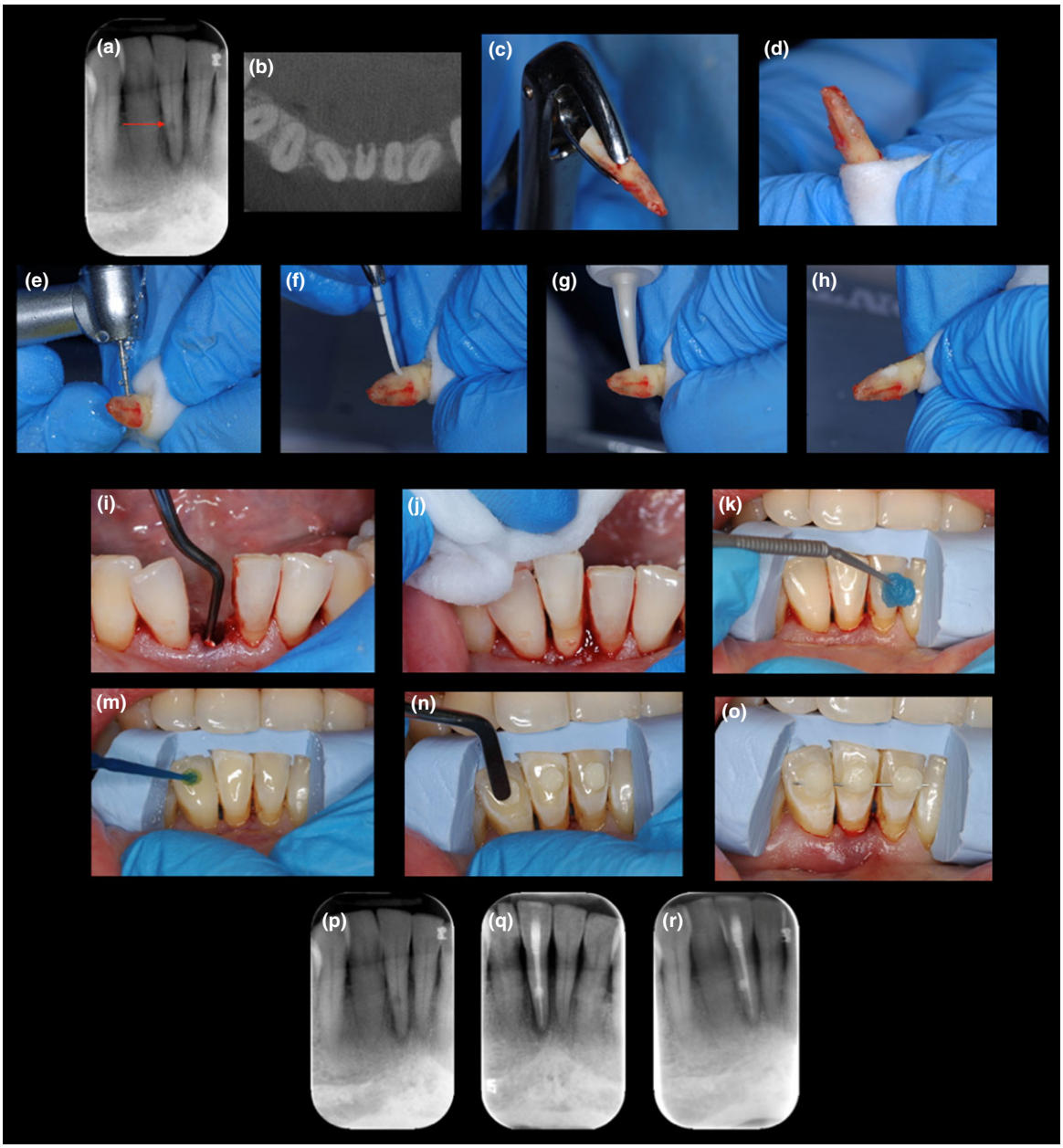

Figure 4 Intentional replantation (a) preoperative radiograph confirms ECR, (b) axial reconstructed CBCT scan confirms the nature of ECR, (c) after root canal treatment was completed, the tooth has been extracted, (d) the tooth is then held with gauze, ECR indicated with yellow arrow (e) to allow the lesion to be excavated, (f) dried with a paper point, (g, h) sealed with glass–ionomer cement sagittal, (i) the extraction socket is gently excavated, (j) the tooth is replanted, (k) a previously made putty index with a window is place over the treatment site to ensure the replanted tooth is in the correct position for etch to be applied prior bonding, (m) composite resin is applied, (n) and then composite (o) for a flexible splint to be applied, (p) pre-treatment radiograph, (q) post-treatment radiograph, (r) 1-year follow-up radiograph confirming radiographic signs of healing.

The relative advantages of intentional reimplantation over alternative treatment such as implant-retained crowns (IRC) include cost-effectiveness, shorter treatment time, fewer appointments and quicker time for the tooth to return to normal function (Choi *et al.* 2014, Torabinejad *et al.* 2015,

Mainkar 2017). Given that the life expectancy of the population is increasing globally (World Health Organisation 2012, Thomson & Ma 2014), the longevity of dental restorations, including IRC, is finite. Therefore, all viable treatment options should be considered to prolong the survival of the natural dentition.

The majority of complications, in particular, external replacement resorption (ERR), occur within the first year after treatment (Emmertsen & Andreasen 1966, Hammarstrom *et al.* 1989, Cho *et al.* 2016). However, long-term follow-up is desirable as late failures have been reported.

There is a lack of consensus as to what is the most appropriate management protocol for intentional reimplantation (Torabinejad *et al.* 2015). It is essential to take a CBCT if treatment is being considered for ECR to assess the nature, that is depth and extent of the lesion(s) (Patel *et al.* 2009, 2016b, Vaz de Souza *et al.* 2017). Three-dimensional models of the tooth, printed from DICOM data can assist in the planning of endodontic treatment (Byun *et al.* 2015), allowing for direct visualization of the defect on the printed model.

Prior to the reimplantation, conventional endodontic treatment should be carried out. The tooth is then atraumatically extracted as described above. Once extracted, the resorptive defect should be debrided, restored and then replanted within 15 min.

Debridement of the defect should be completed under an operating microscope with the tooth being held from the crown. The extracted root should be kept hydrated by gently syringing saline (Becker 2018) or Hank's balanced salt solution (HBSS) (Kratchman 1997, Niemczyk 2001) onto the root during treatment. It has also been suggested that periodic submersion of the tooth in HBSS will help to avoid desiccation (Kratchman 1997).

The granulation tissue within the defect should be curetted, initially with appropriately sized excavators and scalers. Where necessary, a diamond bur with surgical fast handpiece may be used (Fig. 4). Failure to remove all of the granulation tissue will likely result in recurrence (Patel *et al.* 2009). Once debrided, ECR defects should be restored with a direct plastic restoration, for example glass–ionomer cement (GIC) or composite. Fast setting bioactive calcium silicate materials such as Biodentine are suitable for the restoration of exclusively subcrestal ECR defects (Grech *et al.* 2013). Rapid setting limits early material washout and their bioactive/biocompatible properties encourage cementum deposition and new PDL attachment (Yan *et al.* 2010).

The use of two clinicians is desirable, whilst the first operator debrides and restores the ECR defect, and the second operator gently curettes the extraction socket, removing granulation tissue (Becker 2018). After socket curettage is completed, the patient is asked to bite on sterile gauze soaked in saline. Once the tooth is restored, the socket is rinsed with saline and the tooth gently replanted. Initially, the tooth is held with finger pressure before being stabilized with a flexible splint for 2 weeks as per the IADT guidelines for avulsed teeth (Andersson *et al.* 2012).

The patient is then reviewed at appropriate intervals, 2 weeks for the removal of the splint and annually thereafter (Cho *et al.* 2016). Outcome assessment is made on the basis of clinical and radiographic findings.

Although there is a lack of consensus on the ideal management protocol for IR, certain prognostic factors are consistently noted. These include atraumatic extraction to minimize damage to cementum and PDL fibres and a short extraoral dry time (with appropriate irrigant/storage medium). When these are respected, the prognosis for intentional reimplantation is good.

Intentional replantation is a relatively simple, cost-effective and predictable treatment in specific situations.

Periodic review

When a tooth affected by ECR is deemed untreatable, the patient may elect to monitor the tooth until it becomes symptomatic. If this option is chosen, periodic review is indicated to observe the progression of the resorptive process on an annual basis (Figs 5 and 6).

At the review appointment, the patient should be asked if they have experienced symptoms suggestive of pulpal and/or periapical disease. A thorough clinical examination should be carried out. This should include assessment of periodontal health and attachment, resorptive defect progression, colour changes to the crown, status of the pulp and radiographic assessment. The findings of the examination should be discussed with the patient, particularly when any significant changes have been observed.

Following baseline clinical and radiographic assessment (with CBCT), a decision must be made regarding appropriate time intervals for review. There are currently no guidelines on the recall interval for untreated

Figure 5 Review (a–c) Asymptomatic tooth 47 with no clinical signs of endodontic or periodontal disease, but ECR detected at a routine check-up appointment on a (d) bitewing radiograph, (e) periapical radiograph and (f) sagittal CBCT image confirms the untreatable nature of the ECR lesion. After discussing the various treatment options, the patient decided to leave and have it reviewed on periodic basis. At a 3-year review, the tooth remained asymptomatic, clinical examination was also unremarkable; however, (g) periapical radiograph and (h) sagittal CBCT confirmed that the ECR lesion had increased in size. Due to its progression (note the distal aspect of the ECR on the CBCT sagittal slices has increased in size), the patient decided to have the tooth extracted to prevent inevitable symptoms of pulpal and/or periapical disease.

ECR lesions, however, the authors of this article favour annual reviews after the initial assessment.

When the decision has been made to monitor a tooth with untreatable ECR, the patient should be warned of the associated risks and possible sequelae. The potential complications include pain associated with pulpal and/or periapical disease, crown discoloration and/or fracture of the coronal portion of the tooth. Furthermore, the patient should be made aware that progressive (reparative) resorption may complicate the extraction of the tooth and compromise the supporting bone and soft tissues (see next section). A comprehensive discussion with the patient of the potential risks of monitoring a tooth with untreatable ECR is necessary for an informed decision to be made.

Extraction

Extraction is typically the treatment of choice for teeth with untreatable ECR. When ECR is extensive, the cervical region of the tooth may be significantly

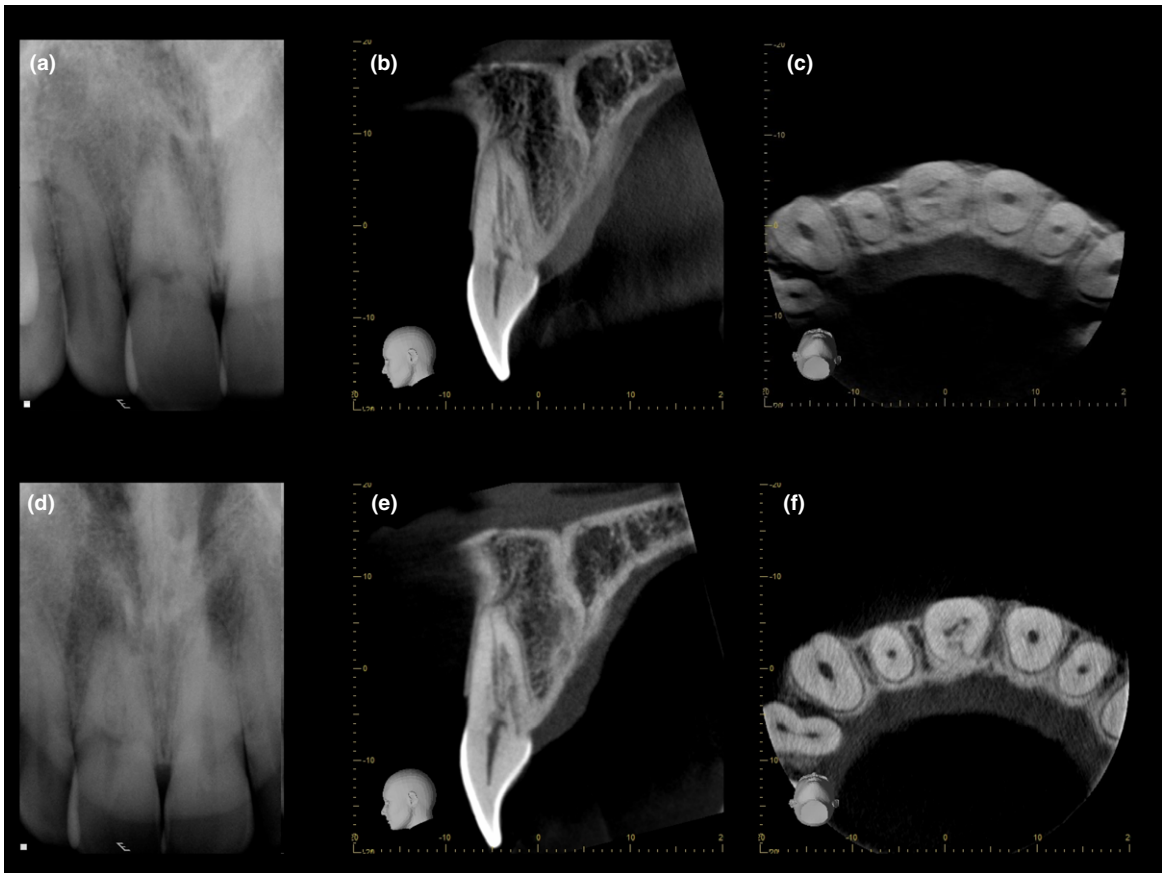

Figure 6 Review asymptomatic tooth 11 with no clinical signs of endodontic or periodontal disease. (a) Periapical radiograph (b) sagittal and (c) axial CBCT slices confirm the reparative nature of the ECR and that it is untreatable. The patient moved abroad for work, on his return to the UK 2 1/2 years later he was seen for a review. He was asymptomatic and clinical examination was unremarkable (d–f) Similar radiographic images taken at the review appointment confirmed that the ECR had remained stable, and therefore, it was agreed that the patient could be kept on periodic review.

weakened predisposing it to fracture during extraction (Fig. 5). Atraumatic extraction techniques, such as those described earlier, should be used to minimize fracture risk, minimize bone destruction and trauma during the procedure (Levitt 2001). However, due to the fragility of teeth with extensive ECR, surgical extraction may be inevitable in certain cases.

As the resorptive lesion will frequently result in breakdown of the periodontal attachment, the adjacent crestal bone is also likely to have been compromised. When the affected tooth is extracted, particularly when the resorptive lesion is located on the buccal aspect, there will be loss of keratinized tissue and alveolar bone which may leave a defect following extraction and subsequently complicate tooth replacement, particularity when located in the aesthetic zone.

Replacement options for the extracted tooth include an implant-retained crown, conventional bridge, resin-bonded bridge and a removable partial denture.

Implant-retained crowns

Single tooth implant-retained crowns have been shown to have 10-year survival rates in excess of 90% and, when necessary, are considered the gold standard option for replacing missing teeth (Wittneben *et al.* 2014, Hjalmarsson *et al.* 2016).

When considering an implant-retained crown to replace a tooth with untreatable ECR, much will depend on the effect of the ECR and extraction procedure on the residual alveolar bone (Fig. 7). This is particularly relevant in the aesthetic zone when an optimal cosmetic result is required. Following

extraction, the quality, thickness, width and height of the interdental bone should be assessed. Socket preservation or grafting procedures may be indicated (Chen & Buser 2014, Morton *et al.* 2014, Atieh *et al.* 2015, Testori *et al.* 2018). In cases where the affected tooth has no signs of periapical pathosis and the buccal cortical plate is intact, and is an adequate thickness of keratinized tissue, it may be appropriate to consider extraction and immediate implant placement (Kan *et al.* 2018).

Resin-bonded bridges

Resin-bonded bridges provide a minimally invasive fixed replacement option for missing teeth that are well accepted by patients (Creugers & De Kanter 2000). They provide a rapid, cost-effective and predictable replacement option for the missing tooth (Tredwin *et al.* 2007, Pjetursson *et al.* 2008). When the enamel of the abutment tooth has been preserved during preparation and adequate occlusal coverage has been provided, resin-bonded bridges have been shown to have a median survival of 9.8 years (Djemal *et al.* 1999). Cantilever resin-bonded bridges demonstrate better survival than fixed-fixed resin-bonded bridges with 5-year survival of 86.3% and 71.9%, respectively (King *et al.* 2015). The most common mode of failure for resin-bonded bridges is debonding (Pjetursson *et al.* 2007); this can usually be managed conservatively and without compromise to the abutment tooth. If the sequelae of the ECR and/or extraction results in a vertical defect beneath

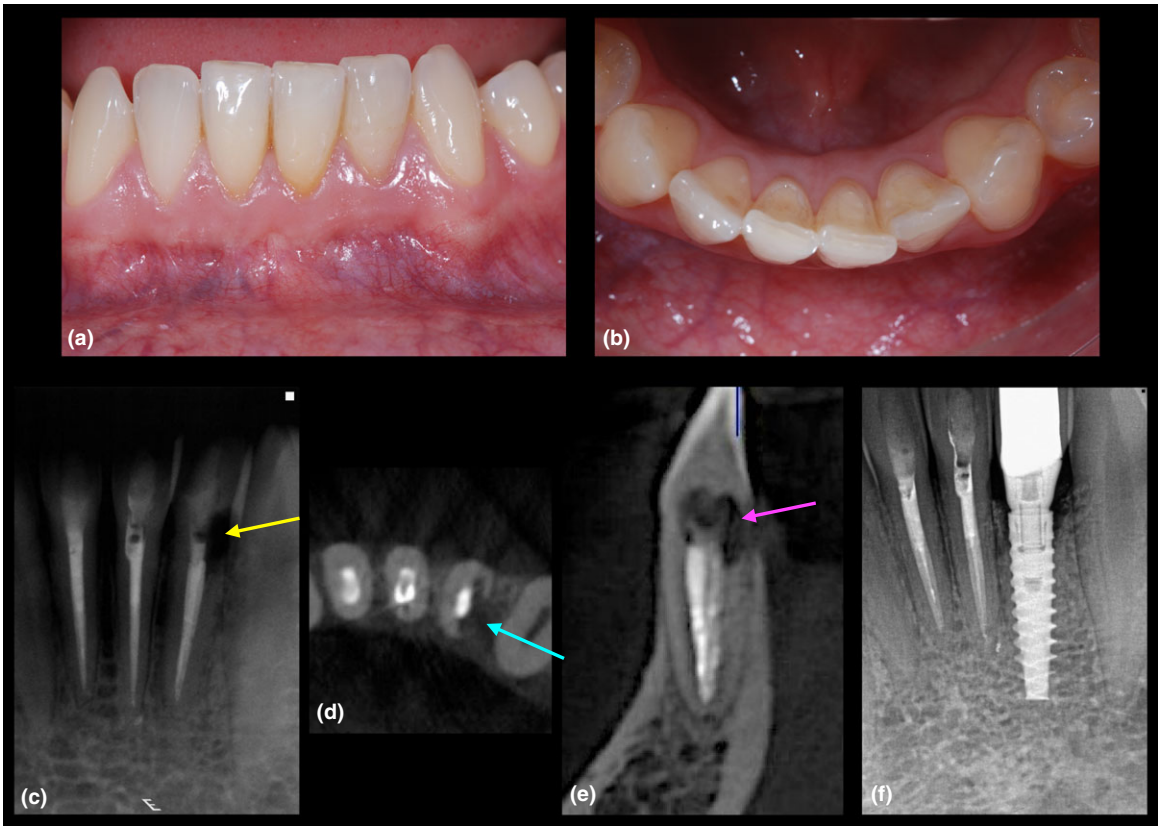

Figure 7 Extraction and replacement with implant-retained crown. (a, b) A 25-year-old male traumatized three mandibular incisors 5 years previously and shortly afterward had root treated carried out. He presented with no symptoms or clinical signs; however, (c) a periapical radiograph revealed ECR (yellow arrow), (d) axial CBCT (blue arrow) and (e) sagittal (purple arrow) CBCT slices confirm that the ECR lesion is inaccessible and therefore untreatable. (f) After discussing the various treatment options with the patient, he decided to have the tooth replaced with an implant-retained crown. Implant placement by Andrew Dawood.

the pontic of the resin-bonded bridge, it may be necessary to replace the deficient soft tissue with pink porcelain to provide adequate aesthetics.

Conventional bridges

A conventional bridge may be chosen to replace an untreatable tooth with ECR. Studies have shown estimated 10-year survival rates of 89.2% for fixed-fixed conventional bridges and 80.3% for cantilever conventional bridges which are comparable with implant survival data (Pjetursson *et al.* 2007). However, the effect of tooth preparation and increased functional loading on the abutment tooth/teeth must be considered when this option is chosen. The most frequent biological complications associated with conventional bridge abutments are loss of pulp vitality and caries. The abutment teeth of conventional bridges are more likely to undergo pulp necrosis than single unit crowns (Cheung *et al.* 2005). In this study, the survival rates for vital pulps after 15 years were 81.2% and 66.2% for metal ceramic crown and bridge abutments, respectively. Furthermore, maxillary anterior teeth were found to have the highest incidence of pulp necrosis.

Complications such as loss of retention and ceramic fractures are more frequent with cantilever conventional bridges than with fixed-fixed conventional bridges. In addition, the incidence of pulp necrosis is higher with cantilever conventional bridges (Pjetursson *et al.* 2007).

Structural, endodontic or periodontal complications associated with the abutment tooth may complicate future management as conventional bridges, particularly fixed-fixed conventional bridges, lack ease of retrievability when the abutment teeth require further intervention.

Removable partial dentures

When a fixed prosthodontic replacement of an untreatable tooth with ECR is not feasible, it may be decided to provide a removable prosthesis. In case of single tooth replacement, a tooth supported removable partial denture may be provided which can be constructed in cobalt chromium. The advantages of tooth supported dentures it that they can be designed with more retention and stability than mucosal borne dentures. In addition, the denture margins can be kept free of the marginal tissues to the benefit of the patient's periodontal health.

Space acceptance

It may be decided to accept the space when an untreatable tooth is extracted. This is particularly relevant when the tooth is not in the aesthetic zone. It has been shown that patients are generally able to fulfil their aesthetic, functional and phonetic demands following the loss of a single molar tooth (Kayser 1981, Elias & Sheiham 1998). However, the patient must be warned of the risk of tilting and/or drifting of teeth adjacent to an edentulous space following the loss of a tooth due to ECR whilst the opposing tooth may be at risk of over eruption (Kaplan 1985). Space acceptance is unlikely to be an appropriate treatment option in the aesthetic zone.

Conclusion

Effective and predictable management of ECR depends on the accurate assessment of the true nature of the lesion. Long-term studies are necessary to determine and assess the impact of the size and nature of ECR on the outcome of treatment.

Conflict of interest

The authors have stated explicitly that there are no conflict of interests in connection with this article.

References

Aeinehchi M, Eslami B, Ghanbariha M, Saffar AS (2003) Mineral trioxide aggregate (MTA) and calcium hydroxide as pulp-capping agents in human teeth: a preliminary report. *International Endodontic Journal* **36**, 225–31.

Andersson L, Andreasen JO, Day P *et al.* (2012) International Association of Dental Traumatology guidelines for the management of traumatic dental injuries: 2—avulsion of permanent teeth. *Dental Traumatology* **28**, 88–96.

Andreasen JO (1981) Relationship between cell damage in the periodontal ligament after replantation and subsequent development of root resorption. A time-related study in monkeys. *Acta Odontologica Scandinavica* **39**, 15–25.

Andreasen JO, Hjorting-Hansen E (1966) Replantation of teeth. I. Radiographic and clinical study of 110 human teeth replanted after accidental loss. *Acta Odontologica Scandinavica* **24**, 263–9.

Arnett TR (2008) Extracellular pH regulates bone cell function. *Journal of Nutrition* **138**, S415–8.

Asgary S, Alim Marvasti L, Kolahdouzan A (2014) Indications and case series of intentional replantation of teeth. *Iranian Endodontic Journal* **9**, 71–8.

Atieh MA, Alsabeeha NH, Payne AG, Duncan W, Faggion CM, Esposito M (2015) Interventions for replacing missing teeth: alveolar ridge preservation techniques for dental implant site development. *Cochrane Database of Systematic Reviews* CD010176. https://doi.org/10.1002/14651858.CD010176.pub2.

Becker BD (2018) Intentional replantation: a critical review. *Journal of Endodontics* **44**, 14–21.

Bender IB, Rossman LE (1993) Intentional replantation of endodontically treated teeth. *Oral Surgery, Oral Medicine, Oral Pathology* **76**, 623–30.

Byun C, Kim C, Cho S *et al.* (2015) Endodontic treatment of an anomalous anterior tooth with the aid of a 3-dimensional printed physical tooth model. *Journal of Endodontics* **41**, 961–5.

Chen ST, Buser D (2014) Esthetic outcomes following immediate and early implant placement in the anterior maxilla — a systematic review. *International Journal of Oral and Maxillofacial Implants* **29**, S186–215.

Cheung GS, Lai SC, Ng RP (2005) Fate of vital pulps beneath a metal-ceramic crown or a bridge retainer. *International Endodontic Journal* **38**, 521–30.

Cho SY, Lee Y, Shin SJ *et al.* (2016) Retention and healing outcomes after intentional replantation. *Journal of Endodontics* **42**, 909–15.

Choi YH, Bae JH, Kim YK *et al.* (2014) Clinical outcome of intentional replantation with pre-operative orthodontic extrusion: a retrospective study. *International Endodontic Journal* **47**, 1168–76.

Creugers NH, De Kanter RJAM (2000) Patients' satisfaction in two long-term clinical studies on resin-bonded bridges. *Journal of Oral Rehabilitation* **27**, 602–7.

Djemal S, Setchell D, King P, Wickens J (1999) Long-term survival characteristics of 832 resin-retained bridges and splints provided in a post-graduate teaching hospital between 1978 and 1993. *Journal of Oral Rehabilitation* **26**, 302–20.

Ee J, Fayad MI, Johnson BR (2014) Comparison of endodontic diagnosis and treatment planning decisions using cone-beam volumetric tomography versus periapical radiography. *Journal of Endodontics* **40**, 910–6.

Elias AC, Sheiham A (1998) The relationship between satisfaction with mouth and number and position of teeth. *Journal of Oral Rehabilitation* **25**, 649–61.

Emmertsen E, Andreasen JO (1966) Replantation of extracted molars: a radiographic and histological study. *Acta Odontologica Scandinavica* **24**, 327–46.

Frank AL (1981) External-internal progressive resorption and its nonsurgical correction. *Journal of Endodontics* **7**, 473–6.

Frank AL, Torabinejad M (1998) Diagnosis and treatment of extracanal invasive resorption. *Journal of Endodontics* **24**, 500–4.

Frank AL, Glick DH, Patterson SS, Weine FS (1992) Long-term evaluation of surgically placed amalgam fillings. *Journal of Endodontics* **18**, 391–8.

Gandolfi MG, Iezzi G, Piattelli A, Prati C, Scarano A (2017) Osteoinductive potential and bone-bonding ability of ProRoot MTA, MTA Plus and Biodentine in rabbit intramedullary model: microchemical characterization and histological analysis. *Dental Materials* **33**, 221–38.

Garrido I, Abella O-ZR, Duran-Sindreu F, Roig M (2016) Combined endodontic therapy and intentional replantation for the treatment of a palatogingival groove. *Journal of Endodontics* **42**, 324–8.

Grech L, Mallia B, Camilleri J (2013) Investigation of the physical properties of tricalcium silicate cement-based root-end filling materials. *Dental Materials* **29**, 20–8.

Greiner JH, Hawkins RD (1991) Intentional replantation. *Endodontic Report* **6**, 11–3.

Grossman LI (1982) Intentional replantation of teeth: a clinical evaluation. *Journal of the American Dental Association* **104**, 633–9.

Hammarstrom L, Blomlof L, Lindskog S (1989) Dynamics of dentoalveolar ankylosis and associated root resorption. *Endodontics & Dental Traumatology* **5**, 163–75.

Heithersay GS (1999) Treatment of invasive cervical resorption: an analysis of results using topical application of trichloroacetic acid, curettage, and restoration. *Quintessence International* **30**, 96–110.

Heithersay GS (2007) Management of tooth resorption. *Australian Dental Journal* **52**, S105–21.

Heithersay GS, Wilson DF (1988) Tissue responses in the rat to trichloroacetic acid–an agent used in the treatment of invasive cervical resorption. *Australian Dental Journal* **33**, 451–61.

Hjalmarsson L, Gheisarifar M, Jemt T (2016) A systematic review of survival of single implants as presented in longitudinal studies with a follow-up of at least 10 years. *European Journal of Oral Implantology* **9**, S155–62.

Jang Y, Lee S-J, Yoon T-C *et al.* (2016) Survival rate of teeth with a c-shaped canal after intentional replantation: a study of 41 cases for up to 11 years. *Journal of Endodontics* **42**, 1320–5.

Kan JYK, Rungcharassaeng K, Deflorian M, Weinstein T, Wang HL, Testori T (2018) Immediate implant placement and provisionalization of maxillary anterior single implants. *Periodontology 2000* **77**, 197–212.

Kaplan P (1985) Drifting, tipping, supraeruption, and segmental alveolar bone growth. *Journal of Prosthetic Dentistry* **54**, 280–3.

Karypidou A, Chatzinikolaou ID, Kouros P, Elisabeth E, Economides N (2016) Management of bilateral invasive cervical resorption lesions in maxillary incisors using a novel calcium silicate-based cement: a case report. *Quintessence International* **47**, 637–42.

Kayser AF (1981) Shortened dental arches and oral function. *Journal of Oral Rehabilitation* **8**, 457–62.

King PA, Foster LV, Yates RJ, Newcombe RG, Garrett MJ (2015) Survival characteristics of 771 resin-retained

bridges provided at a UK dental teaching hospital. *British Dental Journal* **218**, 423–8.

Kingsbury BC Jr, Wiesenbaugh JM Jr (1971) Intentional replantation of mandibular premolars and molars. *Journal of American Dental Association* **83**, 1053–7.

Koh ET, Torabinejad M, Pitt Ford TR, Brady K, McDonald F (1997) Mineral trioxide aggregate stimulates a biological response in human osteoblasts. *Journal of Biomedical Materials Research* **37**, 432–9.

Koubi S, Elmerini H, Koubi G, Tassery H, Camps J (2012) Quantitative evaluation by glucose diffusion of microleakage in aged calcium silicate-based open-sandwich restorations. *International Journal of Dentistry* 105863. https://doi.org/10.1155/2012/105863.

Kratchman S (1997) Intentional replantation. *Dental Clinics of North America* **41**, 603–17.

Levitt D (2001) Atraumatic extraction and root retrieval using the periotome: a precursor to immediate placement of dental implants. *Dentistry Today* **20**, 53–7.

Mainkar A (2017) A systematic review of the survival of teeth intentionally replanted with a modern technique and cost-effectiveness compared with single-tooth implants. *Journal of Endodontics* **43**, 1963–8.

Mavridou AM, Hauben E, Wevers M, Schepers E, Bergmans L, Lambrechts P (2016) Understanding external cervical resorption in vital teeth. *Journal of Endodontics* **42**, 1737–51.

Morton D, Chen ST, Martin WC, Levine RA, Buser D (2014) Consensus statements and recommended clinical procedures regarding optimizing esthetic outcomes in implant dentistry. *International Journal of Oral and Maxillofacial Implants* **29**, S216–20.

Nair PN, Duncan HF, Pitt Ford TR, Luder HU (2008) Histological, ultrastructural and quantitative investigations on the response of healthy human pulps to experimental capping with mineral trioxide aggregate: a randomized controlled trial. *International Endodontic Journal* **41**, 128–50.

Narita H, Itoh S, Imazato S, Yoshitake F, Ebisu S (2010) An explanation of the mineralization mechanism in osteoblasts induced by calcium hydroxide. *Acta Biomaterialia* **6**, 586–90.

Niemczyk SP (2001) Re-inventing intentional replantation: a modification of the technique. *Practical Procedures & Aesthetic Dentistry* **13**, 433–9.

Nosonowitz DM (1972) On intentional replantation. *New York Journal of Dentistry* **42**, 44–7.

Nowicka A, Lipski M, Parafiniuk M *et al.* (2013) Response of human dental pulp capped with biodentine and mineral trioxide aggregate. *Journal of Endodontics* **39**, 743–7.

Parirokh M, Torabinejad M (2010) Mineral trioxide aggregate: a comprehensive literature review-part I: chemical, physical, and antibacterial properties. *Journal of Endodontics* **36**, 16–27.

Parirokh M, Torabinejad M, Dummer PMH (2018) Mineral trioxide aggregate and other bioactive endodontic cements: an updated overview - part I: vital pulp therapy. *International Endodontic Journal* **51**, 177–205.

Patel S, Vincer L (2017) Case report: single visit indirect pulp cap using biodentine. *Dental Update* **44**, 141–5.

Patel S, Kanagasingam S, Pitt Ford T (2009) External cervical resorption: a review. *Journal of Endodontics* **35**, 616–25.

Patel S, Durack C, Ricucci D (2016a) Chapter 20, Root resorption. In: Hargreaves KM, Berman LH, eds. *Cohen's Pathways of the Pulp*, 11th edn. St Louis, MO: Elsevier, pp. 660–83.

Patel K, Mannocci F, Patel S (2016b) The assessment and management of external cervical resorption with periapical radiographs and cone-beam computed tomography: a clinical study. *Journal of Endodontics* **42**, 1435–40.

Patel K, Foschi F, Pop I, Patel S, Mannocci F (2016c) The use of intentional replantation to repair an external cervical resorptive lesion not amenable to conventional surgical repair. *Primary Dental Journal* **5**, 78–83.

Patel S, Foschi F, Mannocci F, Patel K (2018) External cervical resorption: a three-dimensional classification. *International Endodontic Journal* **51**, 206–14.

Pjetursson BE, Bragger U, Lang NP, Zwahlen M (2007) Comparison of survival and complication rates of tooth-supported fixed dental prostheses (FDPs) and implant-supported FDPs and single crowns (SCs). *Clinical Oral Implants Research* **18**, S97–113.

Pjetursson BE, Tan WC, Tan K, Bragger U, Zwahlen M, Lang NP (2008) A systematic review of the survival and complication rates of resin bonded bridges after an observation period of at least 5 years. *Clinical Oral Implants Research* **19**, 131–41.

Rajasekharan S, Martens LC, Cauwels RG, Verbeeck RM (2014) Biodentine material characteristics and clinical applications: a review of the literature. *European Archives of Paediatric Dentistry* **15**, 147–58.

Ramezanali F, Aryanezhad S, Mohammadian F, Dibaji F, Kharazifard MJ (2017) In vitro microleakage of mineral trioxide aggregate, calcium-enriched mixture cement and biodentine intra-orifice barriers. *Iranian Endodontic Journal* **12**, 211–5.

Raskin A, Eschrich G, Dejou J, About I (2012) In vitro microleakage of Biodentine as a dentin substitute compared to Fuji II LC in cervical lining restorations. *Journal of Adhesive Dentistry* **14**, 535–42.

Rodríguez G, Abella F, Durán-Sindreu F, Patel S, Roig M (2017a) Influence of cone-beam computed tomography in clinical decision making among specialists. *Journal of Endodontics* **43**, 194–9.

Rodríguez G, Abella F, Durán-Sindreu F, Patel S, Roig M (2017b) Influence of cone-beam computed tomography on endodontic retreatment strategies among general dental practitioners and endodontists. *Journal of Endodontics* **43**, 1433–7.

Salzano S, Tirone F (2015) Conservative nonsurgical treatment of class 4 invasive cervical resorption: a case series. *Journal of Endodontics* **41**, 1907–12.

Schwartz RS, Robbins JW, Rindler E (2010) Management of invasive cervical resorption: observations from three private practices and a report of three cases. *Journal of Endodontics* **36**, 1721–30.

Sharma SD, Vidya B, Alexander M, Deshmukh S (2015) Periotome as an aid to atraumatic extraction: a comparative double blind randomized controlled trial. *Journal of Maxillofacial and Oral Surgery* **14**, 611–5.

Sultana N, Singh M, Nawal RR *et al.* (2018) Evaluation of biocompatibility and osteogenic potential of tricalcium silicate-based cements using human bone marrow-derived mesenchymal stem cells. *Journal of Endodontics* **44**, 446–51.

Testori T, Weinstein T, Scutellà F, Wang HL, Zucchelli G (2018) Implant placement in the esthetic area: criteria for positioning single and multiple implants. *Periodontology 2000* **77**, 176–96.

Thomson WM, Ma S (2014) An ageing population poses dental challenges. *Singapore Dental Journal* **35**, 3–8.

Tomas-Catala CJ, Collado-Gonzalez M, Garcia-Bernal D *et al.* (2018) Biocompatibility of new pulp-capping materials NeoMTA Plus, MTA Repair HP, and biodentine on human dental pulp stem cells. *Journal of Endodontics* **44**, 126–32.

Torabinejad M, Parirokh M (2010) Mineral trioxide aggregate: a comprehensive literature review—part II: leakage and biocompatibility investigations. *Journal of Endodontics* **36**, 190–202.

Torabinejad M, Dinsbach NA, Turman M *et al.* (2015) Survival of intentionally replanted teeth and implant-supported single crowns: a systematic review. *Journal of Endodontics* **41**, 992–8.

Torabinejad M, Parirokh M, Dummer PMH (2018) Mineral trioxide aggregate and other bioactive endodontic cements: an updated overview - part II: other clinical applications and complications. *International Endodontic Journal* **51**, 284–317.

Tredwin CJ, Setchell DJ, St George G, Weisbloom M (2007) Resin-retained bridges as predictable and successful restorations. *Alpha Omegan* **100**, 89–96.

Trope M (2002) Root resorption due to dental trauma. *Endodontic Topics* **1**, 79–100.

Trope M (2011) Avulsion of permanent teeth: theory to practice. *Dental Traumatology* **27**, 281–94.

Tsukiboshi M (2002) Autotransplantation of teeth: requirements for predictable success. *Dental Traumatology* **18**, 157–80.

Vaz de Souza D, Schirru E, Mannocci F, Foschi F, Patel S (2017) External cervical resorption: a comparison of the diagnostic efficacy using 2 different cone-beam computed tomographic units and periapical radiographs. *Journal of Endodontics* **43**, 121–5.

Weine FS (1980) The case against intentional replantation. *Journal of the American Dental Association* **100**, 664–8.

Wittneben JG, Buser D, Salvi GE, Bürgin W, Hicklin S, Brägger U (2014) Complication and failure rates with implant-supported fixed dental prostheses and single crowns: a 10-year retrospective study. *Clinical Implant Dentistry and Related Research* **16**, 356–64.

World Health Organisation (2012) The European Health Report 'Charting the way to well-being' 2012: where we are: health status in Europe and the case for Health 2020, pp. 1–57. http://www.euro.who.int/__data/assets/pdf_file/0004/197113/EHR2012-Eng.pdf

Yan P, Yuan Z, Jiang H, Peng B, Bian Z (2010) Effect of bioaggregate on differentiation of human periodontal ligament fibroblasts. *International Endodontic Journal* **43**, 1116–21.

Zanini M, Sautier JM, Berdal A, Simon S (2012) Biodentine induces immortalized murine pulp cell differentiation into odontoblast-like cells and stimulates biomineralization. *Journal of Endodontics* **38**, 1220–6.

